

RESEARCH ARTICLE

Reliability of Permanent Mandibular Canine Calcification as an Indicator of Skeletal Maturity in Karnataka Population*

¹R Divyashree, ²MR Dinesh, ³BC Amarnath

¹Assistant Professor, Department of Orthodontics and Dentofacial Orthopedics, Sri Venkateshwara NSVK Dental College and Hospital, Bengaluru, Karnataka, India

²Professor and Head, Department of Orthodontics and Dentofacial Orthopedics, DA Pandu Memorial RV Dental College and Hospital, Bengaluru, Karnataka, India

³Professor, Department of Orthodontics and Dentofacial Orthopedics, DA Pandu Memorial RV Dental College and Hospital Bengaluru, Karnataka, India

Correspondence: R Divyashree, 108, Sai Poorna Heights Apartment, 27th Main, Somasundara Palya, 2nd Sector, HSR Layout, Bengaluru-560102, Karnataka, India, Phone: (+91) 9845693638, e-mail: divyashree.r@gmail.com

Abstract

Aims: The purpose of this study was to assess the reliability of permanent mandibular canine tooth calcification as an indicator of skeletal maturity in Karnataka population by comparing it with the ossification stages of the middle phalanx of the left third finger and also to compare the sexual dimorphism in the timing of these events.

Methods: This study was performed on 100 subjects (50 boys and 50 girls) of South Indian origin aged 10 to 14 years. Radiovisiographs of the middle phalanx of the left third finger and Orthopantomographs were obtained and assessed for the stages of calcification using the methods described by Hagg and Taranger and by Demirjian et al respectively. The correlation between various stages of lower canine calcification and stages of MP3 ossification was assessed for both the sexes using Chi-square test and percentage distributions.

Results: The associations were statistically significant only between MP3-F and canine F stages in both sexes (88% for boys, 59% for girls) and MP3-H and canine H stages in boys (100%). Also girls showed an advanced trend in dental maturation.

Conclusion: The mandibular canine calcification stages alone are not as reliable an indicator as MP3 stages for assessing the skeletal maturity in Karnataka population.

Keywords: Pubertal growth spurt, middle phalanx of the third finger (MP3), mandibular canine calcification stages, radiovisiographs.

INTRODUCTION

The determination of skeletal maturity and growth potential of the patient has a considerable influence on diagnosis, treatment goals, treatment planning, retention and the eventual outcome of treatment in orthodontics and dentofacial orthopedics.¹ Conventionally hand-wrist radiographs or cervical vertebrae on lateral cephalograms have been used to assess skeletal maturity level.

Dental development, particularly of mandibular canine tooth has also been studied in relation to skeletal maturational development.¹⁻⁷ The availability of intraoral or panoramic radiographs in most orthodontic practices, are the practical reasons for attempting to assess skeletal maturity of the patient using dental calcification, without resorting to hand-wrist radiographs. However, the findings relating the dental maturation to skeletal maturation have been contradictory.⁸⁻¹⁰ Also racial and gender variations have been suggested.^{3,4,11}

We attempted to investigate the association of mandibular canine calcification to MP3 ossification stages and its potential to be used as a pubertal growth spurt indicator in Karnataka population. We compared the difference in the timing of these events in boys and girls based on their chronological age to study any sexual dimorphism.

MATERIALS AND METHODS

The sample included 100 subjects, 50 boys and 50 girls of Karnataka origin, registered as patients in the department of Orthodontics and Dentofacial Orthopedics, DA Pandu Memorial RV Dental College and Hospital, Bangalore, India. The age group of 10 to 14 years was chosen, as the pubertal growth spurt events occurring during this period are of clinical importance. The inclusion criteria were untreated, healthy individuals with no history of trauma to face and hand-wrist regions. All subjects were explained

*This paper is from the thesis done by the first author (Dr R Divyashree) for the partial fulfillment of MDS degree in Orthodontics and Dentofacial Orthopedics, submitted to the Rajiv Gandhi University of Health Sciences, Bengaluru, Karnataka, India (April 2008).



Fig. 1: Subject positioned for RVG-MP3



Fig. 2: Digital image of MP3

the need and design of the study and a written consent was obtained. Exact chronological ages in completed years and months were recorded.

Radiovisiographs (Trophy, Radiologie) for the middle phalanx of the third finger (MP3) of left hand of the subjects were made as per the standardized method¹² (Fig. 1). Digital images were obtained using Vixwinpro software programme (Gendex, Dentsply) (Fig. 2). The digital images of MP3 were randomly coded and assessed for the stages of ossification according to the system described by Hagg and Taranger.¹³

MP3 Ossification Stages: Hagg and Taranger Method¹³

MP3-F stage: Start of the curve of pubertal growth spurt

Epiphysis is as wide as metaphysis. Radiolucent gap between epiphysis and metaphysis is wide.

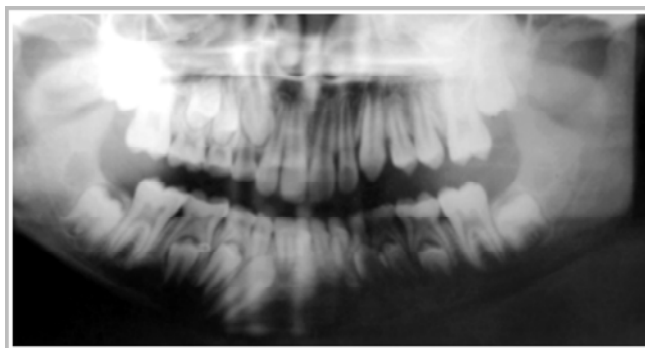


Fig. 3: Coded OPG

MP3-FG stage: Acceleration of the curve of pubertal growth spurt.

Distinct medial and/or lateral border of epiphysis forms line of demarcation at right angle to distal border.

MP3-G stage: Maximum point of pubertal growth spurt

Sides of epiphysis have thickened and cap its metaphysis, forming sharp distal edge on one or both sides. Marked undulations in metaphysis give it “Cupid’s bow” appearance.

MP3-H stage: Deceleration of the curve of pubertal growth spurt.

Fusion of epiphysis and metaphysis begins. Radiolucent gap between epiphysis and metaphysis is narrower.

MP3-I stage: End of pubertal growth spurt

Fusion of epiphysis and metaphysis complete

Panoramic radiographs (Gendex Orthoralix 9200) routinely taken for the treatment purpose were obtained, coded and randomized (Fig. 3). Mandibular left canine tooth was examined in panoramic radiograph for calcification and rated according to the method described by Demirjian, Goldstein and Tanner.¹⁴

Dental Calcification Stages: Demirjian, Goldstein and Tanner Method¹⁴

Stage F: The walls of the pulp canal form an isosceles triangle. The apex ends in a funnel shape. The root length is equal to or greater than the crown height.

Stage G: The walls of the root canal are now parallel and its apical end is still partially open.

Stage H: The apical end of the root canal is completely closed. The periodontal membrane has a uniform width around the root and the apex.

The correlation between various stages of mandibular canine calcification and MP3 ossification was assessed for

all subjects using Chi-square test with the probability value of $p < 0.001$. The mean and standard deviation of chronological ages at each MP3 and canine calcification stage were tabulated to study the difference in the timing of both the events between boys and girls.

RESULTS

The association between various MP3 ossification stages and lower canine calcification stages and their percentage distribution in boys and girls was recorded (Tables 1 and 2, Graphs 1 and 2). At the MP3-F stage for boys, the canine stage F showed a significant association of 88 percent. At MP3-H stage for boys, canine stage H showed a highly significant association of 100 percent. At the MP3-F stage for girls, the canine stage F showed 59 percent distribution indicating a significant association between MP3-F and canine F stages.

Comparing the mean chronological age in years at different MP3 stages indicated that each stage occurs earlier in girls than boys in a range of 0.1 to 1.5 years (Table 3).

The mean chronological age in years at different canine calcification stages was compared between boys and girls

(Table 4). The canine calcification stage F occurred at a mean age of 10.9 years in both the sexes (0 year difference), canine calcification stage G was seen at 12.8 years in boys and 12.2 years in girls (0.6 year difference); canine calcification stage H occurred at 13.8 years in boys and 12.8 years in girls (1 year difference).

DISCUSSION

In this study, we attempted to assess the reliability of permanent mandibular canine calcification as an indicator of skeletal maturity in subjects of Karnataka origin by comparing it with MP3 ossification stages. We found that the mandibular canine stage F showed a significant association with the MP3-F stage indicating the onset of pubertal growth in both boys (88 percent) and girls (59 percent). The canine stage H showed a highly significant association with the MP3-H stage in boys (100 percent) indicative of the period of decelerating growth velocity. This is in contrast to the study by Krailassiri et al¹ on Thai individuals in whom canine stage H coincided with the MP3-G stage in majority of the boys indicating peak growth period. In this study the canine stage G did not show

Table 1: Association of MP3 and mandibular canine calcification stages

MP3 stages	Mandibular canine calcification stages					
	F		G		H	
	Boys	Girls	Boys	Girls	Boys	Girls
F	30 (88%)*	7 (59%)*	0 (0%)	4 (22%)	0 (0%)	0 (0%)
FG	3 (9%)	3 (25%)	5 (45.5%)	3 (17%)	0 (0%)	0 (0%)
G	0 (0%)	1 (8%)	5 (45.5%)	5 (28%)	0 (0%)	2 (10%)
H	1 (3%)	0 (0%)	1 (9%)	6 (33%)	5 (100%)**	9 (45%)
I	0 (0%)	1 (8%)	0 (0%)	0 (0%)	0 (0%)	9 (45%)
Total subjects	34	12	11	18	5	20

() percent distribution

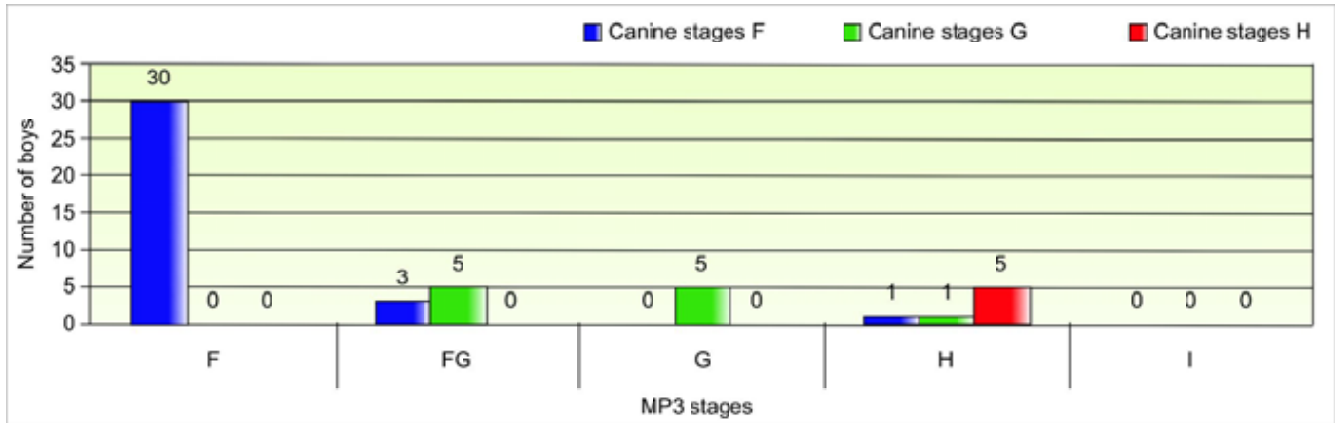
**highly significant; *significant association at p -value < 0.001

Table 2: Measurement of association between MP3 stages and canine calcification stages

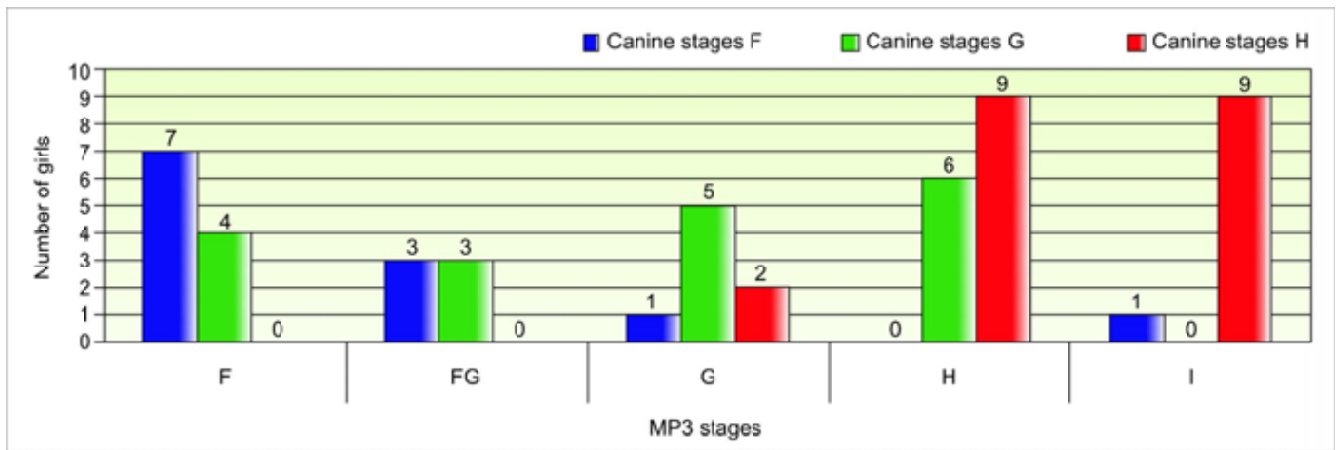
MP3 stages	Boys	Girls
F	0.76	0.66
FG	0.38	0.19
G	0.56	0.23
H	0.78	0.21
I	-	0.20

Table 3: Age distribution for MP3 stages

MP3 stages	Chronological age (years)				
	Boys		Girls		Gender difference Mean
	Mean	SD	Mean	SD	
F	10.9	0.8	10.8	0.7	0.1
FG	12.0	1.0	11.1	0.9	0.9
G	13.4	0.6	11.9	1.5	1.5
H	13.5	0.8	12.9	0.9	0.6
I	-	-	13.1	1.0	-



Graph 1: Association of MP3 and mandibular canine calcification stages in boys



Graph 2: Association of MP3 and mandibular canine calcification stages in girls

Table 4: Age distribution for canine calcification stages

Canine calcification stages	Chronological age (years)				Gender difference Mean
	Boys		Girls		
	Mean	SD	Mean	SD	
F	10.9	0.8	10.9	1.1	0
G	12.8	0.9	12.2	1.1	0.6
H	13.8	0.8	12.8	1.1	1.0

statistically significant association with any MP3 stages in both the sexes. However, in the study by Chertkow and Fatti,³ the canine stage G coincided with MP3-G stage significantly in Caucasian children while in Black children no significant relationship was found, suggesting racial variations.

Hence according to our findings, canine calcification stages are not indicative of peak growth period (stage G), but only the beginning (stage F) in both the sexes and deceleration of growth (stage H) only in boys. This study further confirms the influence of racial and gender factors

on the lack of concordance among the results of previous studies. The predominant ethnic origin of the population, climate, nutrition, socioeconomic levels, and urbanization are indicated as the causative factors of these racial variations.

In this study, girls were found to mature earlier than boys by a mean age of 0.78 years. This is in agreement with the previous studies by Chapman,¹⁵ Fishman,¹⁶ Krailassiri et al¹ and Uysal et al.² Similar to skeletal maturation, dental maturation occurred earlier in girls than in boys by almost a year and was also completed earlier in girls. Interestingly, the canine calcification stage F occurred at almost the same age in both the sexes, but as the root formation progressed the calcification stages occurred at a significantly later age in boys compared to girls with a progressive widening in the age difference. This suggests that a sexual dimorphism exists in mandibular canine tooth formation with an advanced trend in dental calcification in girls. This is in contrast to previous studies. Chertkow and Fatti³ reported

that no significant sex differences were evident in the distribution of tooth mineralization stages for mandibular canine. Chertkow,⁴ Krailassiri et al¹ and Uysal et al² have reported that the tooth mineralization relative to the skeletal maturation indicated an advanced trend in boys compared to girls. Conversely, Basaran et al¹⁷ stated that boys showed late dental development. This discrepancy between dental and chronological age could be attributed to racial variations between individuals in their rates of maturation since the previous studies were conducted on a different ethnic population.

CONCLUSIONS

The following conclusions were obtained:

- The stages of root formation of mandibular canine indicated only the onset of pubertal growth spurt for both the sexes and a period of decelerating growth velocity in boys.
- However the relationship was not consistent for all the stages of skeletal maturation and differed between boys and girls.
- A sexual dimorphism existed in canine tooth formation similar to skeletal maturation with an advanced trend in dental calcification in girls.

Hence the mandibular canine tooth calcification is not a very reliable skeletal maturity indicator in Karnataka population and is not recommended as a substitute to other conventional skeletal maturity indicators.

ACKNOWLEDGMENTS

Dr Dharma RM, Dr Prashanth CS, Dr Akshai Shetty KR, Departments of Orthodontics and Dentofacial Orthopedics, DA Pandu Memorial RV Dental College and Hospital, Bengaluru, Karnataka, India.

REFERENCES

1. Krailassiri S, Anuwongnukroh N, Dechkunakorn S. Relationships between dental calcification stages and skeletal

- maturity indicators in Thai individuals. *Angle Orthod* 2002;72:155-65.
2. Uysal T, Sari Z, Ramoglu SI, Basciftci FA. Relationships between dental and skeletal maturity in Turkish subjects. *Angle Orthod* 2004;74:657-63.
3. Chertkow S, Fatti P. Relationship between tooth mineralization and early radiographic evidence of ulnar sesamoid. *Angle Orthod* 1979;49:282-88.
4. Chertkow S. Tooth mineralization as an indicator of pubertal growth spurt. *Am J Orthod Dentofacial Orthop* 1980;77:79-91.
5. Sierra A. Assessment of dental and skeletal maturity. *Angle Orthod* 1987;57:194-207.
6. Coutinho S, Buschang PH, Miranda F. Mandibular canine calcification stages and skeletal maturity. *Am J Orthod Dentofacial Orthop* 1993;104:262-68.
7. Flores-Mir C, Mauriciob FR, Orellanad MF, Majore PW. Association between growth stunting with dental development and skeletal maturation stage. *Angle Orthod* 2005;75:935-40.
8. Demirjian A, Buschang PH, Tanguay R, and Patterson DK. Interrelationships among measures of somatic, skeletal, dental and sexual maturity. *Am J Orthod Dentofacial Orthop* 1985;88:433-38.
9. Sahin Salam AM, Gazilerli U. The relationship between dental and skeletal maturity. *J Orofac Orthop* 2002;63:454-62.
10. Lewis AB. Comparison of dental and skeletal ages. *Angle Orthod* 1991;71:87-92.
11. Mappes MS, Harris EF, and Behrents RG. Regional differences in tooth and bone development. *Am J Orthod Dentofacial Orthop* 1992;101:145-51.
12. Abdel-Kader HM. The potential of digital dental radiography in recording the adductor sesamoid and the MP3 stages. *Br J Orthod* 1999;26:291-93.
13. Hagg U, Taranger J. Maturation indicators and the pubertal growth spurt. *Am J Orthod Dentofacial Orthop* 1982;82:299-309.
14. Demirjian A, Goldstein H, Tanner JM. A new system of dental age assessment. *Hum Biol* 1973;45:211-27.
15. Chapman SM. Ossification of the adductor sesamoid and adolescent growth spurt. *Angle Orthod* 1972;42:236-44.
16. Fishman LS. Radiographic evaluation of skeletal maturation. *Angle Orthod* 1982;52:88-111.
17. Ba_aran G, Ozer T, Hamamci N. Cervical vertebral and dental maturity in Turkish subjects. *Am J Orthod Dentofacial Orthop* 2007;131:447.e13-20.